GI Excellence, Inc.

Gastroenterology Associates

Office Fax: (951) 658-6476 · Office Hours: 9 a.m. to 5 p.m, M - F

Milan S. Chakrabarty, M.D.
General Gastroenterology

Indraneel Chakrabarty, M.D., M.A.
Advanced & Interventional Gastroenterology

Sandra Del Valle, PA-C
Gastroenterology Physician Assistant

Kathleen Linke, PA-C
Gastroenterology Physician Assistant

Two Locations:
HEMET
1003 E. Florida Avenue · Suite 101 · Hemet, CA 92543 · (951) 652-2252
TEMECULA
31515 Rancho Pueblo Rd. · Suite 202 · Temecula, CA 92592
(951) 383-6001 (By appt.)

MANOMETRY (Esophageal)

What is esophageal manometry?

Esophageal manometry is a procedure for determining how well the muscle of the esophagus works when diseases of the muscle are suspected by measuring pressures (manometry) generated by the esophageal muscles.

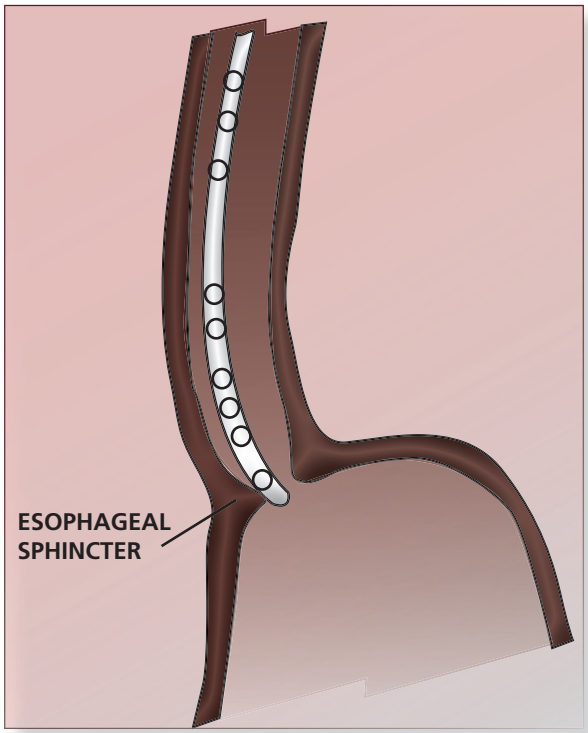

When is esophageal manometry used?

Esophageal manometry is used primarily in three situations:

- To evaluate the esophagus when there is reflux (regurgitation) of stomach acid and contents back into the esophagus (gastroesophageal reflux disease or GERD)
- To determine the cause of problems with swallowing food (dysphagia)
- When there is chest pain that may be coming from the esophagus

How is esophageal manometry performed?

At the start of the esophageal manometry procedure, one nostril is anesthetized with a numbing lubricant. A flexible plastic tube approximately one-eighth inch in diameter is then passed through the anesthetized nostril, down the back of the throat, and into the esophagus as the patient swallows. Once inside the esophagus, the tube allows the pressures generated by the esophageal muscle to be measured when the muscle is at rest and during swallows. The procedure usually takes 15 to 20 minutes.

How is esophageal manometry used to assist in the diagnosis of diseases and conditions?

The esophagus is a muscular tube that connects the throat with the stomach. When food is propelled by a swallow from the mouth into the esophagus, a wave of muscular contraction starts behind the food in the upper esophagus and travels down the entire length of the esophagus (referred to as the body of the esophagus), thus propelling the food in front of the wave through the esophagus and into the stomach. At the upper and lower ends of the esophagus are two short areas of specialized muscle called the upper and lower esophageal sphincters. At rest (that is, when there has been no swallow) the muscle of the sphincters is active and generates pressure that prevents anything from passing through them. As a result, material within the esophagus cannot back up into the throat, and stomach acid and contents cannot back up into the esophagus. When a swallow occurs, both the sphincters relax for a few seconds to allow food to pass through the esophagus into the stomach.

The most common use for esophageal manometry is to evaluate the lower esophageal sphincter and the muscle of the body of the esophagus in patients who have gastroesophageal reflux disease (GERD). Manometry often can identify weakness in the lower esophageal sphincter that allows stomach acid and contents to back up into the esophagus. It also may identify abnormalities in the functioning of the muscle of the esophageal body that may add to the problem of reflux.

Manometry can help diagnose several esophageal conditions that result in food sticking after it is swallowed. For example, achalasia is a condition in which the muscle of the lower esophageal sphincter does not relax completely with each swallow. As a result, food is trapped within the esophagus. Abnormal function of the muscle of the body of the esophagus also may result in food sticking. For instance, there may be failure to develop the wave of muscular contraction (as can occur in patients with scleroderma) or the entire esophageal muscle may contract at one time (as in an esophageal spasm). Manometry reveals an absence

Continue next page...

of the wave in the first case and the contraction of the muscle everywhere in the esophagus at the same time, or spasm, in the second case.

The abnormal functioning of the esophageal muscle also may cause episodes of severe chest pain that can mimic heart pain (angina). Such pain may occur if the esophageal muscle goes into spasm or contracts too strongly. In either case, esophageal manometry may identify the muscular abnormality.

What limitations are there to the use of esophageal manometry?

There are several situations in which esophageal manometry may not demonstrate the esophageal abnormality that is responsible for a patient's problem. For example, many patients with GERD have transient (coming and going infrequently) but prolonged relaxation (minutes rather than seconds) of the lower sphincter as the cause of their reflux. Such relaxations may be missed in the short period during which the manometric study is being conducted. Similarly, if a patient is having infrequent episodes of chest pain due to esophageal spasm, for example, every few days or weeks, the spasm may not be seen during a short manometric study. There have been attempts to get around these problems by using portable equipment and prolonged manometry for two or more days.

What are the side-effects of esophageal manometry?

Although esophageal manometry is uncomfortable, the procedure is minimally painful because the nostril through which the tube is inserted is anesthetized. Once the tube is in place, patients talk and breathe normally. The side-effects of esophageal manometry are minor and include mild sore throat, nosebleeds, and, uncommonly, sinus problems due to irritation and blockage of the ducts leading from the sinuses and into the nose. Occasionally, during insertion, the tube may enter the larynx (voice box) and cause choking. When this happens, the problem usually is recognized immediately, and the tube is rapidly removed. Care must be used in passing the tube in patients who are unable to easily swallow on command because without a swallow to relax the upper esophageal sphincter the tube often doesn't enter the esophagus but instead may enter the larynx.

Are there alternatives to esophageal manometry?

There are no good alternatives to esophageal manometry. However, special radiological studies using X-rays and swallowed barium (video-fluoroscopic swallowing studies) are available. These studies can provide complementary information, for example, by identifying anatomical abnormalities such as narrowing of the esophagus that also can cause food to stick.

www.gi-excellence.com

Emphasizing endoscopy excellence,
we give our patients the comfort of clarity.